
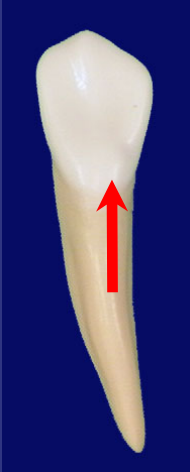
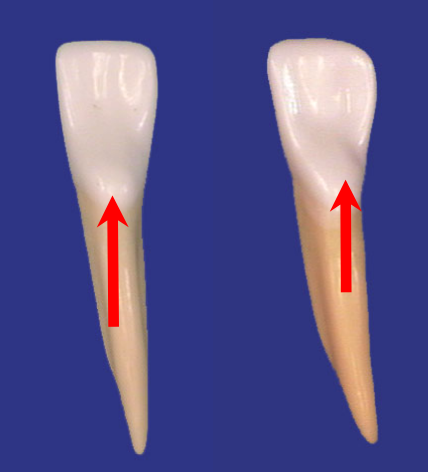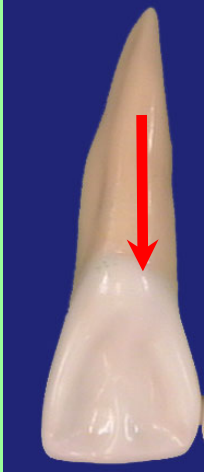


Anterior Teeth

cingulum that is located in the center





Anterior Teeth

anterior tooth

a

- **mandibular central incisor**

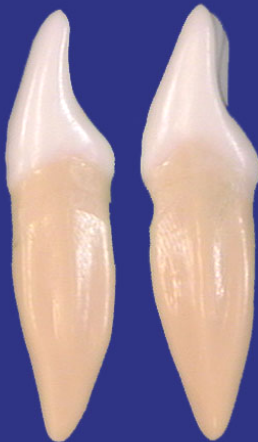
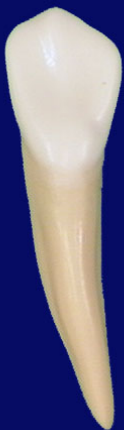
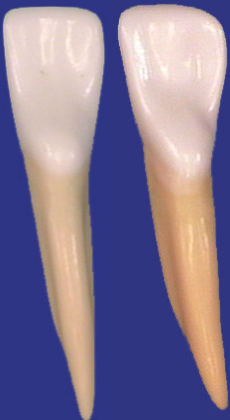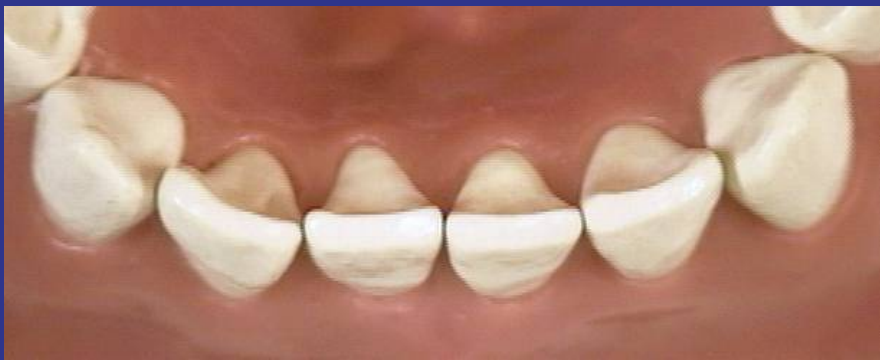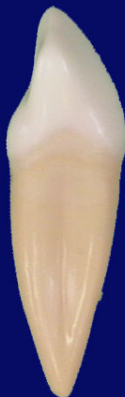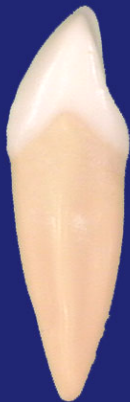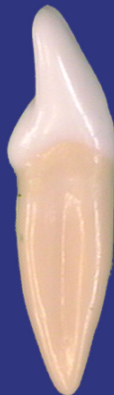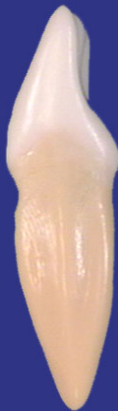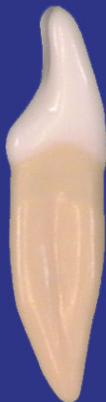Anterior Teeth

anterior teeth

all mandibular







Anterior Teeth

EXCEPTION?

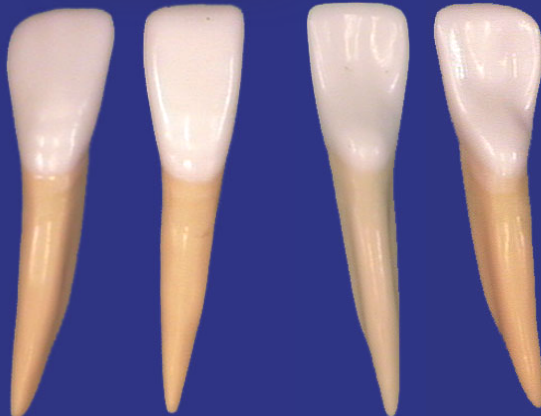
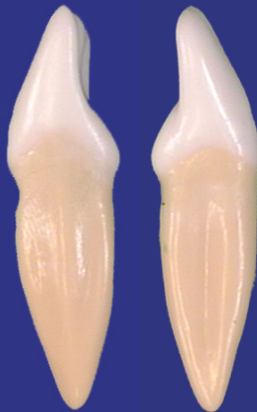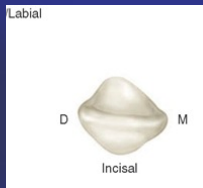
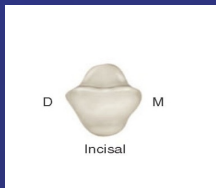
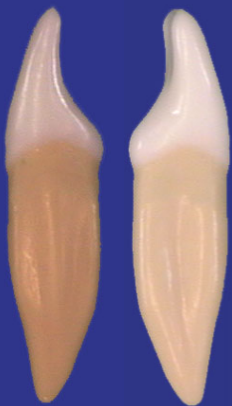


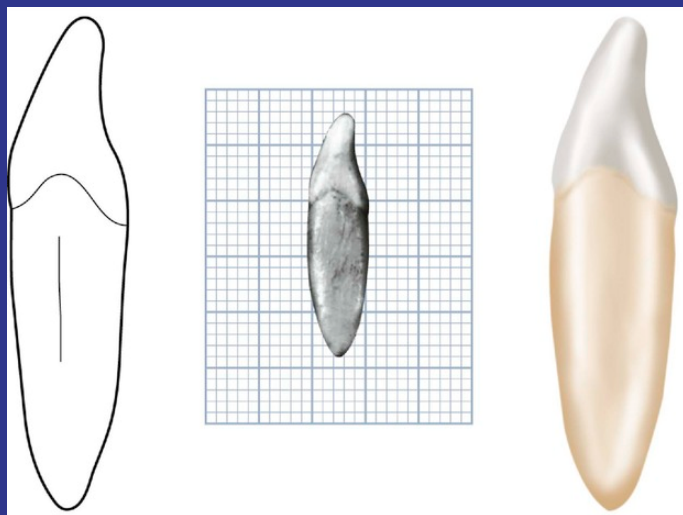
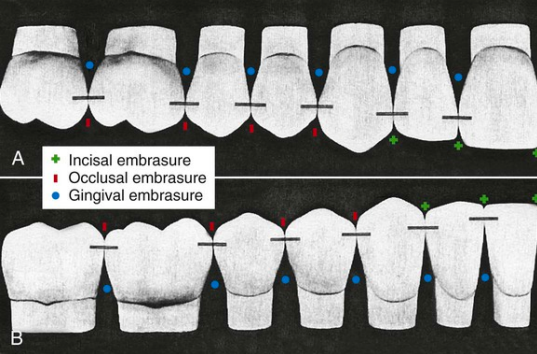
- the CEJ curvatures are greater on the distal than the mesial

Anterior Teeth

lateral or central incisors







Anterior Teeth

following criteria



- difference in rotation of the crown on the root

Anterior Teeth

The mesial and distal aspects

The base

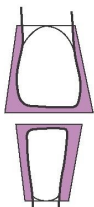
the

apex

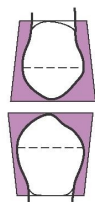




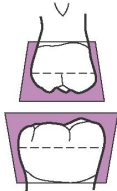
A



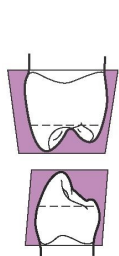
B



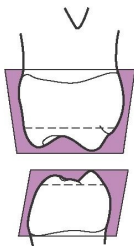
C



D



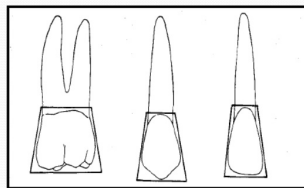
E



F

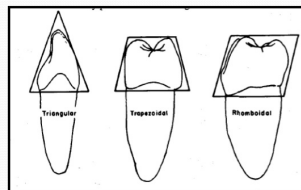
Facial and Lingual Surfaces

TOOTH	SHAPE
ALL ANTERIORS (LABIAL & LINGUAL)	TRAPEZOID
ALL POSTERIORS (BUCCAL & LINGUAL)	TRAPEZOID



Mesial and Distal Surfaces:

TEETH	SHAPE
ANTERIOR TEETH	TRIANGULAR
MAXILLARY POSTERIOR TEETH	TRAPEZOIDAL
MANDIBULAR POSTERIOR TEETH	RHOMBOIDAL



Anterior Teeth

triangle

cervical portion



- the first statement is true, the second is false

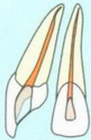Anterior Teeth

pulp canal

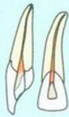area

UPPER JAW

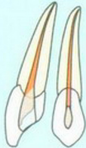ISO 50 or 60



ISO 50
ISO 35- 40
(if curved)

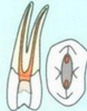


ISO 50 or 60



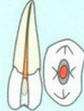B: ISO 35 or 40
P: ISO 40

1 canal:
ISO 50 or 60

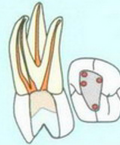

B: ISO 35 or 40
P: ISO 40

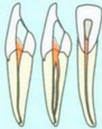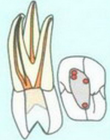1 canal:
ISO 50 or 60



MBs: ISO 35 or 40
DB: ISO 35 or 40
P: ISO 50 or 60

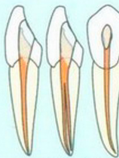


MBs: ISO 35 or 40
DB: ISO 35 or 40
P: ISO 50 or 60



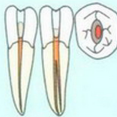
B: ISO 40
L: ISO 40

1 canal:
ISO 50



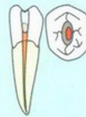
B: ISO 40
L: ISO 40

1 canal:
ISO 50



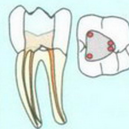
B: ISO 40
P: ISO 40

1 canal:
ISO 50 or 60



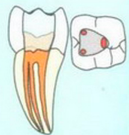B: ISO 40
P: ISO 40

1 canal:
ISO 50 or 60



MB: ISO 35 or 40
ML: ISO 35 or 40

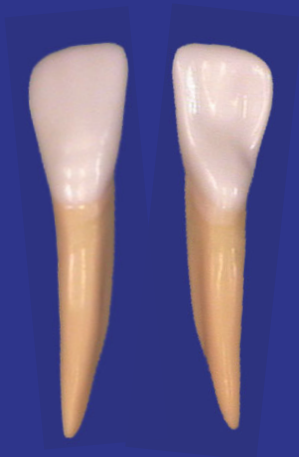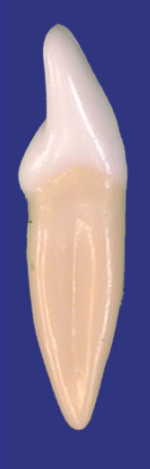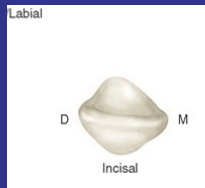
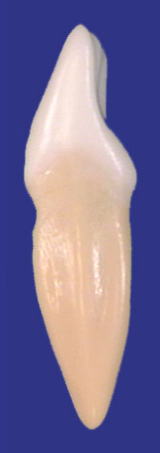D: ISO 50 or 60
2 Ds: ISO 40 or 50



MB: ISO 35 or 40
ML: ISO 35 or 40

D: ISO 50 or 60
2 Ds: ISO 40 or 50

LOWER JAW



Anterior Teeth



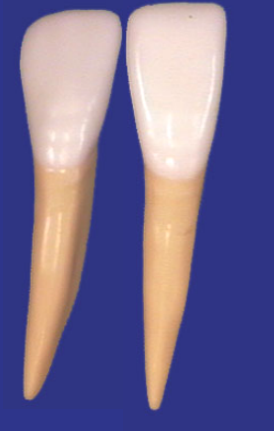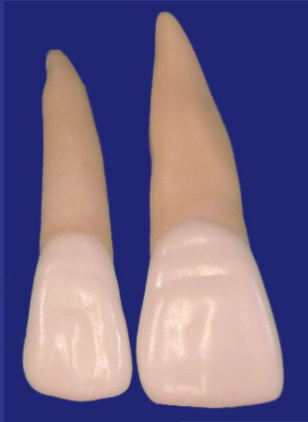mandibular lateral incisor?

- an elliptical shape, wider in the mesiodistal direction in the pulp chamber, but wider in the faciolingual direction in the mid-root area

Anterior Teeth

line angles





Anterior Teeth

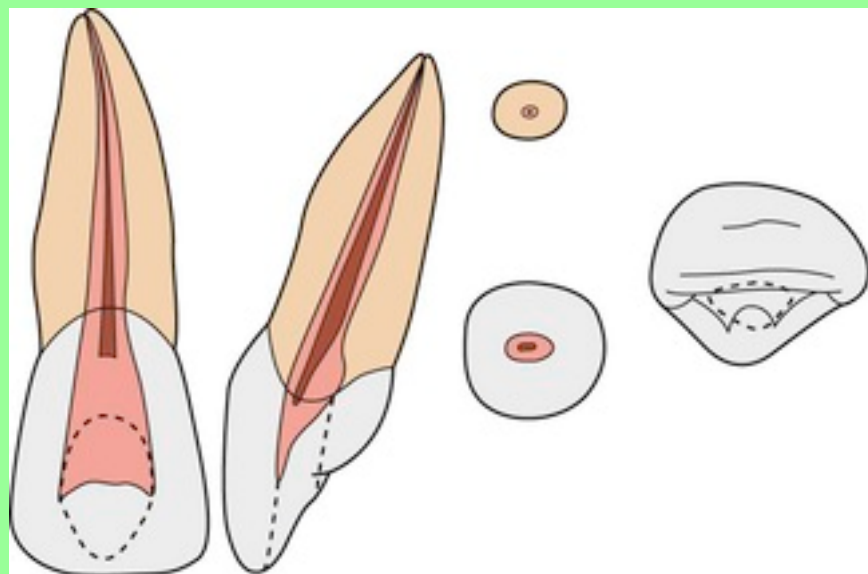
least square?

- distoincisal of the mandibular lateral incisor



The pulp chamber





Anterior Teeth

_____ is wider in the mesiodistal

- maxillary central incisor



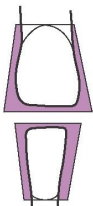
Anterior Teeth

facial or lingual aspect

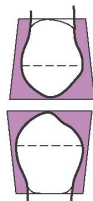




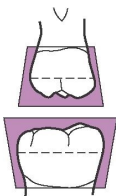
A



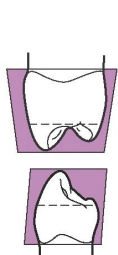
B



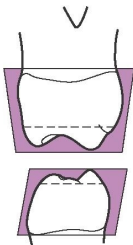
C



D



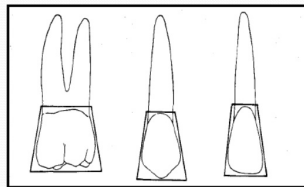
E



F

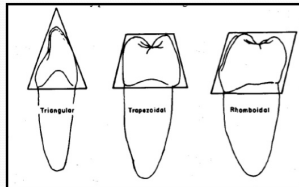
Facial and Lingual Surfaces

TOOTH	SHAPE
ALL ANTERIORS (LABIAL & LINGUAL)	TRAPEZOID
ALL POSTERIORS (BUCCAL & LINGUAL)	TRAPEZOID



Mesial and Distal Surfaces:

TEETH	SHAPE
ANTERIOR TEETH	TRIANGULAR
MAXILLARY POSTERIOR TEETH	TRAPEZOIDAL
MANDIBULAR POSTERIOR TEETH	RHOMBOIDAL



Anterior Teeth

anterior teeth

- trapezoidal outline

